

## Bleeding Duodenal Ulcer After Roux-en-Y Gastric Bypass Surgery

Marc Zerey, MD, FRCSC; Lee B. Sigmon, BS; Timothy S. Kuwada, MD; B. Todd Heniford, MD; and Ronald F. Sing, DO

**Postoperative upper gastrointestinal bleeding, though rare, is a potentially fatal complication of gastric bypass surgery that usually occurs a few months postoperation. The current report describes a 57-year-old man with a bleeding duodenal ulcer who underwent Roux-en-Y gastric bypass surgery 12 years earlier. With an increasing number of gastric bypass surgeries performed each year, physicians must be aware of their patients' altered gastrointestinal anatomy and physiology—as well as the potential for pathophysiology.**

*J Am Osteopath Assoc.* 2008;108:25-27

The prevalence of morbid obesity has reached previously unheard of levels, with 5.1% of American adults in 2002 having a body mass index of 40 or higher—meeting federal guidelines for “extremely obese.”<sup>1,2</sup> With a greater number of morbidly obese adults and higher demand for surgical solutions, it is not surprising that the number of bariatric surgical procedures performed in the United States swelled from 13,365 in 1998 to 72,177 in 2002.<sup>3</sup> In fact, an estimated 205,000 bariatric surgeries were performed in 2007 alone.<sup>4</sup> However, with more bariatric procedures comes an upsurge in postsurgical complications.

Gastric bypass surgery is the most common bariatric surgical procedure, accounting for 88% of all operations in 2002 for patients with obesity.<sup>3</sup> As physicians treat a growing number of postoperative patients, a sound knowledge of these patients' altered gastrointestinal anatomy, physiology, and potential for pathophysiology is needed. Although postoperative upper gastrointestinal bleeding resulting from gastric or duodenal ulceration is rarely reported, it is a potentially fatal complication.<sup>5,6</sup> We report a patient with a bleeding duodenal ulcer occurring 12 years after Roux-en-Y gastric bypass was performed.

### Report of Case

A 57-year-old man presented to the emergency department complaining of weakness, light-headedness, and melena. On admission, the patient was hypotensive (blood pressure, 84/44 mm Hg), tachycardic (heart rate, 126 beats per minute), and tachypneic (respiratory rate, 34 breaths per minute). His medical history included chronic renal insufficiency, coronary artery disease, hypertension, micronodular cirrhosis, and peptic ulceration. The patient also had Roux-en-Y gastric bypass surgery 12 years prior. The patient was a nonsmoker and was not on nonsteroidal anti-inflammatory medications (NSAIDs). It was unknown whether he had a history of *Helicobacter pylori* infection.

Laboratory results revealed a hemoglobin level of 7.6 g/dL and no coagulopathy. Despite multiple blood transfusions—2 units of packed red blood cells administered the day of admission and the day after admission—the patient's anemia persisted. Peroral endoscopy exposed a typical postgastric bypass anatomy without a source of bleeding. Subsequent celiac angiography revealed active bleeding in the duodenal area, and Gelfilm embolization was performed. However, as a result of ongoing hemorrhage, a surgical exploration was undertaken. An intraoperative upper endoscopy was performed through an anterior gastrotomy (Figure 1). A 1-cm bleeding ulcer was identified in the posterolateral wall of the duodenum (Figure 2).

The patient was taken immediately to the operating room. The endoscopy was then performed directly through a hole made in the stomach. The endoscope was withdrawn, and an anterior transverse duodenotomy was performed. After the duodenal ulcer was oversewn with interrupted 3-0 silk sutures, the duodenotomy and gastrotomy were closed in two layers. The patient had an unremarkable recovery and was discharged 5 days postoperation with a lifelong prescription for a proton pump inhibitor.

### Comment

The most common etiology of upper gastrointestinal bleeding in patients who have undergone Roux-en-Y gastric bypasses is marginal ulceration at the gastrojejunal anastomosis.<sup>7</sup> The overall incidence of marginal ulceration after such procedures may be as high as 7%.<sup>8</sup> As demonstrated in animal experiments<sup>9</sup> and evidenced in humans,<sup>10</sup> the gastric pouch created during gastric bypass procedures is associated with decreased

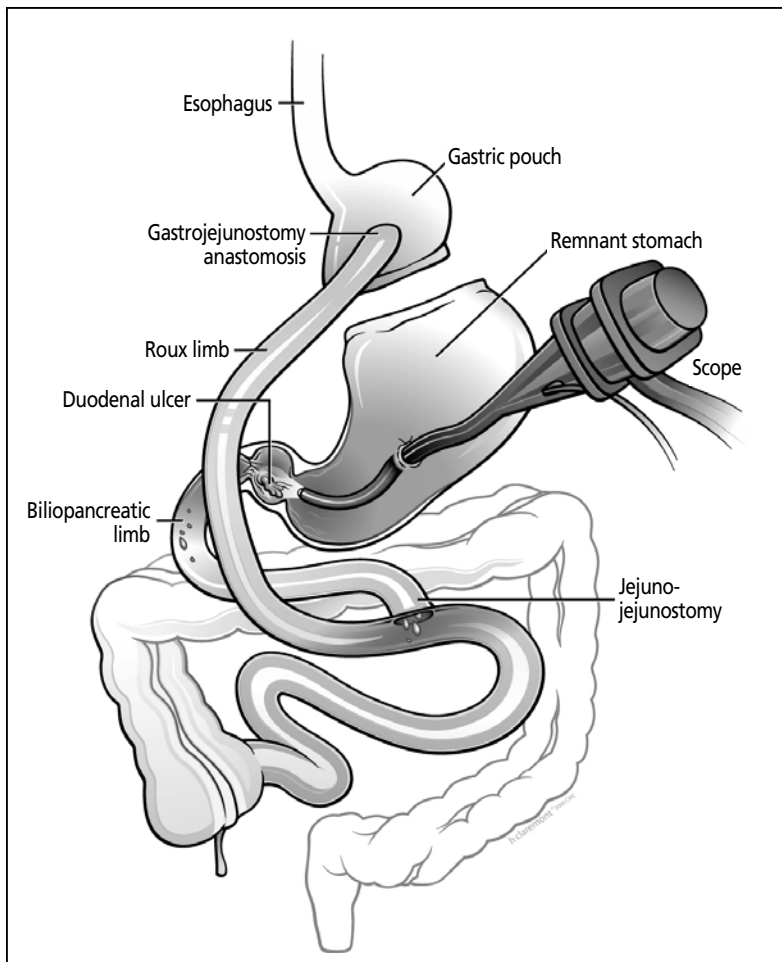
From the Division of Gastrointestinal and Minimally Invasive Surgery in the Department of Surgery at the Carolinas Medical Center in Charlotte, NC.

Address correspondence to Ronald F. Sing, DO, Department of General Surgery, Carolinas Medical Center, 1000 Blythe Blvd, MEB 601, Charlotte, NC 28203-5812.

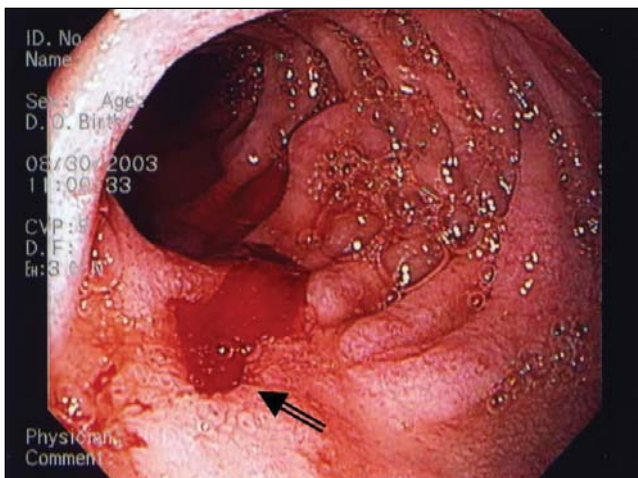
E-mail: rsing@carolinas.org

Submitted December 8, 2006; revision received March 27, 2007; accepted March 27, 2007.

## CASE REPORT



**Figure 1.** Intraoperative endoscopy in patient who underwent Roux-en-Y gastric bypass. The endoscope is introduced through an incision made in the gastric remnant to localize the bleeding ulcer in the duodenum.



**Figure 2.** Endoscopic image of a bleeding duodenal ulcer, indicated by the black arrow.

acid production. However, both Mason et al<sup>9</sup> and Flickinger et al<sup>11</sup> have demonstrated the bypassed segment's ability to maintain an acidic—and therefore ulcer-friendly—environment. Although gastrin levels have been shown to decrease after gastric bypass, the vagus nerves are generally preserved and the excluded gastric mucosa retains its ability to respond to vagal and hormonal stimuli, again maintaining an acidic environment in the bypassed stomach and duodenum. Patient history of smoking, NSAID use, and *Helicobacter pylori* infection—though the former two were absent and the latter was unknown in the patient described in the current study—can also increase the incidence of ulcers.

The diagnosis of duodenal and antral ulcers in patients who have had Roux-en-Y gastric bypass surgery is difficult because altered anatomy denies endoscopic access to the distal stomach and duodenum. For this reason, and to prevent ulceration, some surgeons advocate lifelong proton-pump inhibitors for all patients undergoing gastric bypass surgery.<sup>12</sup>

In cases where upper gastrointestinal hemorrhage is suspected, peroral endoscopy should be performed to exclude marginal ulceration at the gastrojejunal anastomosis. Bleeding may be localized using technetium Tc 99m red blood cells, a celiac angiogram, or a combination of both. Once bleeding is identified, angiographic techniques can be used to attempt to stop the

bleeding. However, if the patient requires transfusion or becomes hemodynamically unstable, operative exploration is mandatory. In our experience, it has been impossible to visualize the duodenum using transcolonic endoscopy—even with longer pediatric colonoscopes—because Roux limbs are commonly longer than 100 cm.

### Conclusion

As more and more Americans become obese each year and as nonoperative options fail to bring these adults to a healthy weight, the explosion of bariatric surgery as witnessed in recent years will likely continue.<sup>3,13,14</sup> These procedures, particularly Roux-en-Y gastric bypass surgery, present primary care physicians with new diagnostic and therapeutic challenges. However, an improved understanding of patients' altered anatomy and subsequent comorbidities will ensure physician competence and improved patient care.

### References

1. Hedley AA, Ogden CL, Johnson CL, Carroll MD, Curtin LR, Flegal KM. Prevalence of overweight and obesity among US children, adolescents, and adults, 1999-2002. *JAMA*. 2004;291:2847-2850.

2. Body Mass Index (BMI). Partnership for Health Weight Management Web site. Available at: <http://www.consumer.gov/weightloss/bmi.htm>. Accessed January 15, 2008.
  3. Santry HP, Gillen DL, Lauderdale DS. Trends in bariatric procedures. *JAMA*. 2005;294:1909-1917.
  4. Taylor K. Bariatric surgery fact sheet. American Society for Metabolic & Bariatric Surgery Web site. Available at: [http://www.asbs.org/Newsite07/media/fact-sheet1\\_bariatric-surgery.pdf](http://www.asbs.org/Newsite07/media/fact-sheet1_bariatric-surgery.pdf). Accessed January 9, 2008.
  5. Bjorkman DJ, Alexander JR, Simons MA. Perforated duodenal ulcer after gastric bypass surgery. *Am J Gastroenterol*. 1989;84:170-172.
  6. Spires WV, Morris DM. Bleeding duodenal ulcer after gastric bypass procedure for obesity. *South Med J*. 1987;80:1325-1326.
  7. Yang CS, Lee WJ, Wang HH, Huang SP, Lin JT, Wu MS. Spectrum of endoscopic findings and therapy in patients with upper gastrointestinal symptoms after laparoscopic bariatric surgery. *Obes Surg*. 2006;16:1232-1237.
  8. Rasmussen JJ, Fuller W, Ali MR. Marginal ulceration after laparoscopic gastric bypass: an analysis of predisposing factors in 260 patients. *Surg Endosc*. 2007;21:1090-1094.
  9. Mason EE, Munns JR, Kealey GP, Wangler R, Clarke WR, Cheng HF, et al. Effect of gastric bypass on gastric secretion. *Am J Surg*. 1976;131:162-168.
  10. Pope GD, Goodney PP, Burchard KW, Proia RR, Olafsson A, Lacy BE, et al. Peptic ulcer/stricture after gastric bypass: a comparison of technique and acid suppression variables. *Obes Surg*. 2002;12:30-33.
  11. Flickinger EG, Sinar DR, Pories WJ, Sloss RR, Park HK, Gibson JH. The bypassed stomach. *Am J Surg*. 1985;149:151-156.
  12. Gumbs AA, Duffy AJ, Bell RJ. Incidence and management of marginal ulceration after laparoscopic Roux-Y gastric bypass. *Surg Obes Relat Dis*. 2006;2:460-463.
  13. Nguyen NT, Root J, Zainabadi K, Sabio A, Chalifoux S, Stevens CM, et al. Accelerated growth of bariatric surgery with the introduction of minimally invasive surgery. *Arch Surg*. 2005;140:1198-1202.
  14. Steinbrook R. Surgery for severe obesity. *N Engl J Med*. 2004;350:1075-1079.
-